

# Pregnancy during the course of Cushing's syndrome: a case report and literature review

Sofia Pilar Ildefonso-Najarro<sup>1</sup>, Esteban Alberto Plasencia-Dueñas<sup>1</sup>,  
Cesar Joel Benites-Moya<sup>2</sup>, Jose Carrion-Rojas<sup>3</sup> and Marcio Jose Concepción-Zavaleta<sup>1</sup>

<sup>1</sup>Division of Endocrinology, Guillermo Almenara Irigoyen National Hospital, Lima, Peru, <sup>2</sup>National University of Trujillo, School of Medicine, Trujillo, Peru, and <sup>3</sup>Metabolism and Reproduction Unit, Division of Endocrinology, Guillermo Almenara Irigoyen National Hospital, Lima, Peru

Correspondence  
should be addressed  
to C J Benites-Moya  
**Email**  
[cjbenitesmoya@gmail.com](mailto:cjbenitesmoya@gmail.com)

## Summary

Cushing's syndrome is an endocrine disorder that causes anovulatory infertility secondary to hypercortisolism; therefore, pregnancy rarely occurs during its course. We present the case of a 24-year-old, 16-week pregnant female with a 10-month history of unintentional weight gain, dorsal gibbus, nonpruritic comedones, hirsutism and hair loss. Initial biochemical, hormonal and ultrasound investigations revealed hypokalemia, increased nocturnal cortisolemia and a right adrenal mass. The patient had persistent high blood pressure, hyperglycemia and hypercortisolism. She was initially treated with antihypertensive medications and insulin therapy. Endogenous Cushing's syndrome was confirmed by an abdominal MRI that demonstrated a right adrenal adenoma. The patient underwent right laparoscopic adrenalectomy and anatomopathological examination revealed an adrenal adenoma with areas of oncocytic changes. Finally, antihypertensive medication was progressively reduced and glycemic control and hypokalemia reversal were achieved. Long-term therapy consisted of low-dose daily prednisone. During follow-up, despite favorable outcomes regarding the patient's Cushing's syndrome, stillbirth was confirmed at 28 weeks of pregnancy. We discuss the importance of early diagnosis and treatment of Cushing's syndrome to prevent severe maternal and fetal complications.

## Learning points:

- Pregnancy can occur, though rarely, during the course of Cushing's syndrome.
- Pregnancy is a transient physiological state of hypercortisolism and it must be differentiated from Cushing's syndrome based on clinical manifestations and laboratory tests.
- The diagnosis of Cushing's syndrome during pregnancy may be challenging, particularly in the second and third trimesters because of the changes in the maternal hypothalamic-pituitary-adrenal axis.
- Pregnancy during the course of Cushing's syndrome is associated with severe maternal and fetal complications; therefore, its early diagnosis and treatment is critical.

## Background

Cushing's syndrome (CS) is a relatively rare disorder having incidence rate of 2–25 per million per year in the general population. Pregnancy rarely occurs during the course of CS because the resultant hypercortisolism can lead to anovulation and infertility (1).

The first case of pregnancy in CS was reported in 1953 by Hunt and McConahey. Since then, <200 cases have

been reported in the literature (2). No such cases have been reported in Peru.

Placental production of corticotropin-releasing hormone (CRH) and adrenocorticotrophic hormone (ACTH) along with increased maternal production of estrogen-induced corticosteroid binding globulin leads to physiological hypercortisolism during pregnancy. Hence, physicians face a

clinical overlap, in which many features of CS (weight gain, fatigue, edema, hypertension, hyperglycemia, stretch marks, mood changes etc.) can also be attributed to pregnancy (2, 3, 4). Thus, their coexistence represents a diagnostic challenge.

The predominant etiology of CS in pregnant women is adrenal adenoma (in 40–60% of the cases), whereas in nonpregnant women it is pituitary lesions (Cushing's disease in 70% of the cases); although the exact cause of this difference is still unknown (1, 5).

The fetus is normally protected from maternal hypercortisolism by placental enzymes such as 11 $\beta$ -hydroxysteroid dehydrogenase type 2, which converts glucocorticoids to inactive metabolites (4). However, pregnant women with CS have a much higher risk of both fetal (premature birth, infections, hypoglycemia, respiratory distress and stillbirth) and maternal (gestational diabetes, preeclampsia and maternal death) complications (1). Therefore, early diagnosis and treatment of CS must be ensured to prevent these outcomes.

## Case presentation

The patient presented was a previously healthy 24-year-old, 16-week pregnant Peruvian female with an obstetric

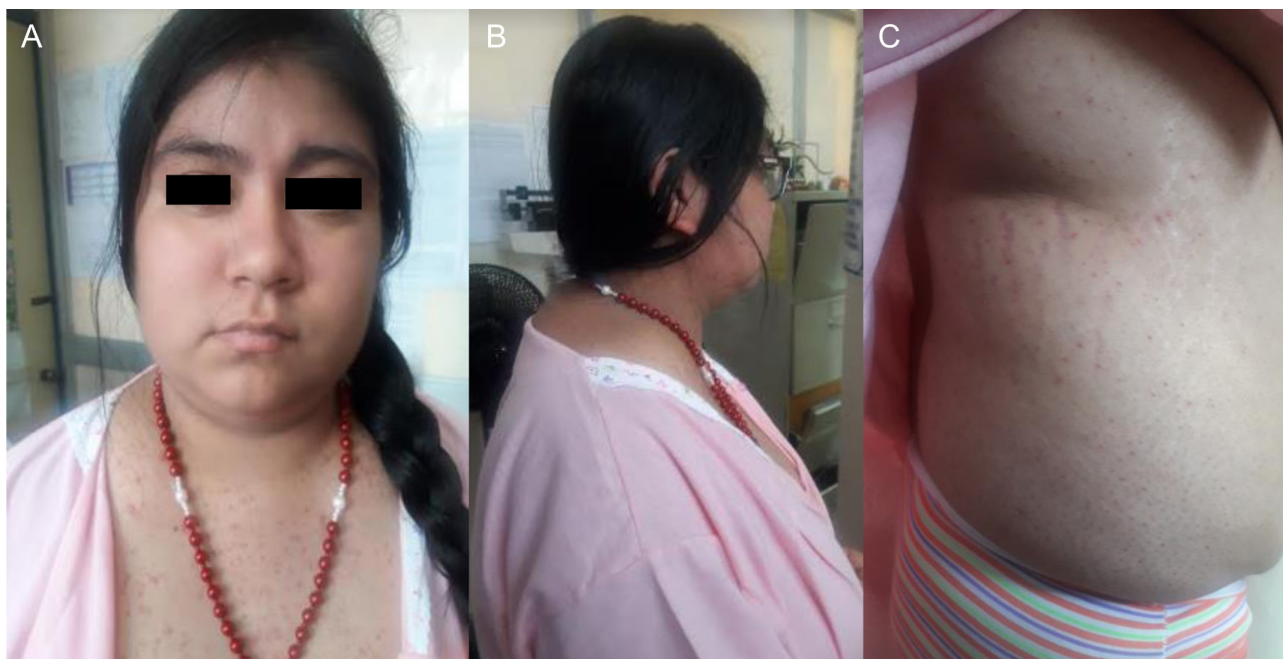history of spontaneous abortion 1 year ago and a threatened abortion at 14th week of pregnancy. The patient had noncontributory family history and no previous surgical history. The patient was admitted with a 10-month history of unintentional centripetal weight gain of approximately 20 kg (body height, 155 cm; body weight, 76.8 kg; BMI, 31.96 kg/m<sup>2</sup>) associated with dorsocervical fat pad accumulation (dorsal gibbus); decreased lean body mass; proximal weakness of lower extremities; and painless, nonpruritic comedones located on the face, chest and abdomen. Two months prior to admission, the patient developed hair growth in male-like pattern and alopecia. At that time, she reported 8 weeks of amenorrhea, and pregnancy was confirmed by urinary human chorionic gonadotropin (hCG) test and transvaginal ultrasound. Ten days before admission, the patient complained of a moderately severe, occipital headache with an acutely elevated in blood pressure of 170/100 mmHg. Three days later, because of persistence of symptoms, she was brought to the emergency department of a community hospital. Initial laboratory tests showed hypercortisolemia at 00:00 h and 08:00 h and hypokalemia (K<sup>+</sup>=2.3 mEq/L). An abdominal ultrasound revealed a right, well-demarcated, ovoid-shaped, solid, hypoechoic mass with the

**Table 1** Patient's relevant blood tests.

	Pre-surgery	Post-surgery	Normal range <sup>a</sup>
Complete blood count			
Hemoglobin, g/dL	16.6	14	
WBC, cells/mm <sup>3</sup>	9900	8200	
Eosinophils, %	0	0	
Lymphocytes, %	15	22	
Basophils, %	0	0	
Monocytes, %	5	3	
Neutrophils, %	80	75	
Platelets	290,000/mm <sup>3</sup>	350,000/mm <sup>3</sup>	
Glucose, mg/dL	130	84 mg/dL	
Creatinine, mg/dL	0.7		
Serum electrolytes, mEq/L			
Na	138	142	
K	2.8	3.3	
Hepatic panel			
Alkaline phosphatase, U/L	70		
AST, U/L	57		
ALT, U/L	22		
GGT, U/L	91		
Total bilirubin, mg/dL	0.5		
Urinary free cortisol, $\mu$ g/24 h	2380	26	10–110
08:00-h cortisol, $\mu$ g/dL	36.13		5–25
Midnight cortisol, $\mu$ g/dL	32.94		5–25
ACTH, pg/mL	<5		
TSH, $\mu$ U/mL	0.355		

<sup>a</sup>Normal range to a pregnant female.

ACTH, adrenocorticotropic hormone; TSH, thyroid-stimulating hormone.

**Figure 1**

Clinical manifestations. Moon face (A), dorsal gibbus (B) and comedone-like lesions on thoracoabdominal region (C).

dimension of  $32.5 \times 22.8$  mm that suggested to be an adrenal adenoma. Seven days later, the patient was transferred to the endocrinology department of our hospital with the following diagnoses: nulliparous secundigravida at 16th week of pregnancy and endogenous hypercortisolism secondary to adrenal adenoma.

At admission, her vital signs were normal except blood pressure of 180/100 mmHg. Physical examination revealed a moon face, dorsal gibbus, ecchymosis in the upper extremities, hirsutism (modified Ferriman–Gallwey score of 8), thick violaceous striae and nonpruritic comedones on the face, chest, and abdomen (Fig. 1). The rest of the physical examination was unremarkable.

## Investigation

Biochemical and hormonal investigation (Table 1) showed hypokalemia ( $K^+ = 2.8$  mEq/L), fasting glycemic level of 133 mg/dL, mildly elevated liver transaminases, elevated urinary free cortisol (2380  $\mu\text{g}/24$  h; normal range: 10–110  $\mu\text{g}/24$  h), altered cortisol circadian rhythm with increased 08:00-h serum cortisol (36.13  $\mu\text{g}/\text{dL}$ ; normal range: 5–25  $\mu\text{g}/\text{dL}$ ), increased midnight serum cortisol (32.94  $\mu\text{g}/\text{dL}$ ; normal range: 5–25  $\mu\text{g}/\text{dL}$ ) and normal midnight ACTH (6.34 pg/mL; normal range: <10 pg/mL, suppressed).

Abdominal MRI without contrast demonstrated a  $30 \times 30 \times 23$  mm mass arising from the right adrenal gland,

with smooth and regular borders and lightly hypointense in T1-weighted out-of-phase images (Fig. 2).

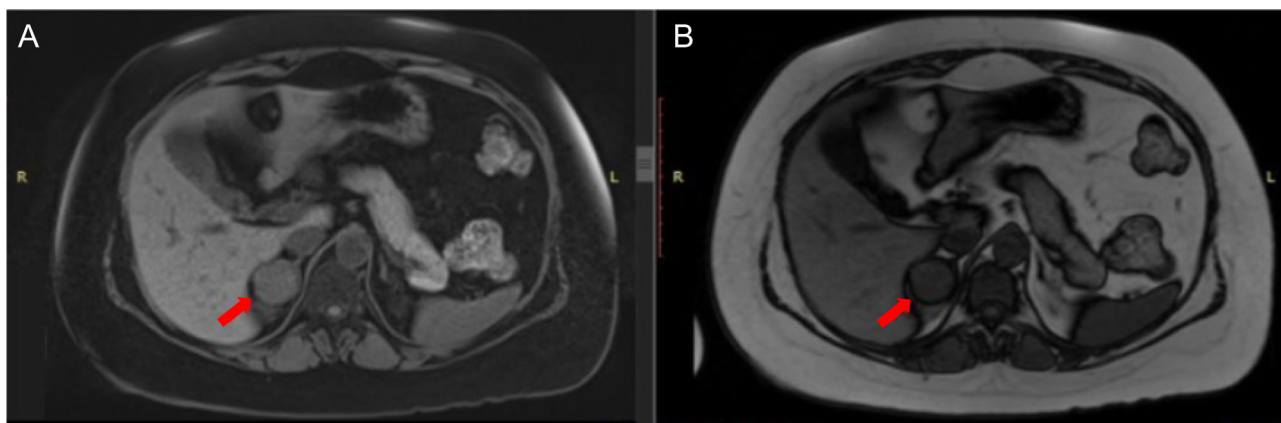
ACTH-independent Cushing's syndrome secondary to adrenal adenoma was confirmed.

## Treatment

As soon as the findings were found to be consistent with hypercortisolism, the patient was treated with methyl dopa 3000 mg/day, insulin NPH 40 units before breakfast and at bedtime; rapid-acting insulin 10 units before each meal and i.v. potassium replacement. Based on literature review and the fact that medical treatment (steroidogenesis inhibitors) may increase fetal toxicity in the first two trimesters of gestation, a right laparoscopic adrenalectomy was performed at 18th week of gestation, without complications. An adrenal adenoma of dimension  $3 \times 3 \times 2$  cm was removed. Anatomopathological examination revealed an adrenal adenoma with areas of oncocytic changes.

## Outcome and follow-up

After removal of the adenoma, blood pressure control was adequate and antihypertensive medication was progressively reduced. Glycemic control and hypokalemia reversal were achieved; thus, insulin and i.v. potassium

**Figure 2**

Abdominal MRI demonstrates a right adrenal adenoma (A). T1-weighted out-of-phase image is shown (B).

were no longer needed. A long-term corticosteroid therapy was needed because of the resultant adrenal insufficiency, it consisted initially of prednisone 7.5 mg/day followed by 5 mg/day. During follow-up, despite favorable outcomes regarding CS, stillbirth was confirmed at 28 weeks of pregnancy. The cause of the stillbirth was unknown because a fetal autopsy was not performed due to patient preferences. Three months after surgery, serum sodium and potassium levels were 136 mEq/L and 3.8 mEq/L, respectively; fasting glycemia was 84 mg/dL and urinary free cortisol was 26 µg/24 h. The patient is currently following-up at our hospital's endocrinology clinic.

## Discussion

Pregnancy is considered a transient physiological state of hypercortisolism; however, it lacks specific clinical manifestations of CS (1). Pregnancy rarely occurs during the course of CS because of the infertility secondary to the hypogonadotropic hypogonadism caused by glucocorticoid and androgen excess. Moreover, amenorrhea or oligomenorrhea occurs in 75% of women with CS (6).

The etiology of CS varies between pregnant and non-pregnant women. Lindsay *et al.* studied 136 pregnancies of 122 women with CS (7). In pregnant women, adrenal adenoma is more prominent (40–60%) than Cushing's disease (33%) and ectopic hypercortisolism is very rare (7, 8).

The diagnosis of CS during pregnancy is usually challenging because of hypercortisolemia, for which there are several underlying mechanisms. Hypercortisolism is related to high maternal levels of estrogen-induced

corticosteroid binding globulin. Furthermore, placental CRH and ACTH production increases progressively from seventh week until the end of pregnancy, leading to increased circulating cortisol levels that reach values in the range seen with CS (9).

Urinary free cortisol excretion remains normal in the first trimester of pregnancy and increases by 1.4 and 1.6 times in the second and third trimesters, respectively. The urinary free cortisol test is not reliable after the first trimester, unless levels are greater than three times the upper limit of normal (10). The circadian cortisol rhythm is preserved during pregnancy. Ambroziak *et al.* suggested that baseline nocturnal salivary cortisol values used in healthy adults can be used in pregnancy; hence, salivary cortisol should be considered one of the best initial diagnostic tools for CS in pregnancy (11). The dexamethasone suppression test is less reliable in pregnancy because of its high false-positive rate (7).

In the case presented here, the patient had clinical manifestations of hypercortisolism during pregnancy, associated with urinary free cortisol levels greater than three times the upper limit of normal levels and absence of normal circadian cortisol rhythm. CS was confirmed. The etiology was determined by suppressed ACTH levels and imaging compatible with adrenal adenoma.

A high rate of maternal complications may arise from uncontrolled CS during pregnancy (7). Even in treated cases, some patients develop complications such as preeclampsia or premature delivery. While taking decisions regarding therapy, following factors must be considered: the stage of pregnancy, etiology, severity of hypercortisolism and potential benefit of treatment. The most commonly described maternal complications include: hypertension (68%), diabetes (25%), preeclampsia



(14%), osteoporosis and fractures (5%), heart failure (3%) and maternal death (2%) (7, 12). The most common fetal complication is prematurity (43%), followed by intrauterine growth restriction (21%), stillbirth (6%), spontaneous abortion or intrauterine death (5%) and hypoadrenalism (2%). However, higher fetal survival rates were observed in women treated during pregnancy (7).

In patients with adrenal adenomas, therapeutic options include unilateral adrenalectomy during pregnancy or medical treatment followed by surgery after childbirth (13). Adrenalectomy during the second trimester significantly reduces maternal and fetal morbidities. In the third trimester, medical treatment and early delivery are preferred (10). However, there are case reports of successful unilateral adrenalectomy in the third trimester (14). In the present case, diagnosis was made at the 16th week of pregnancy, and the patient underwent laparoscopic adrenalectomy without complications at the 18th week of pregnancy. After unilateral adrenalectomy, relative adrenal insufficiency occurred because of the increased normal requirements of corticosteroids during the rest pregnancy. Thus, a daily replacement dose of corticosteroids was needed. Hydrocortisone is the corticosteroid of election; however, it was not available for this patient. Hence, an equivalent dose of prednisone was used. Long-term therapy consisted of low-dose daily prednisone, initially 7.5 mg/day followed by 5 mg/day. Pregnancy was intended to be maintained until term with reversal of hypertension, hyperglycemia and hypokalemia. However, during follow-up, stillbirth occurred at 28th week of pregnancy.

In 2006, Blanco *et al.* reported a case of pregnancy during the course of CS (15). Metyrapone administration was started at eighth week of gestation, and laparoscopic adrenalectomy was performed at the 16th week. Adrenal insufficiency was treated with daily glucocorticoids. Finally, there was spontaneous vaginal delivery at 30th week of gestation.

Medical treatment of CS in pregnancy is usually withheld to minimize potential teratogenic exposures and induction of fetal adrenal insufficiency. Nevertheless, it might be indicated prior to surgery, in patients with persistent clinical manifestations despite surgery and in those in whom the surgery cannot be performed. In this case, medical treatment was not considered the first-line option because the relevant available information was scarce. Treatment plans depend on gestational age, the clinician's experience and the general condition of the patient.

Steroidogenesis inhibitors, particularly metyrapone, are the most commonly used therapies. There have been no adverse effects on maternal liver function or fetal development in the small number of reported cases. However, fetal hypoadrenalism can occur. In addition, it may exacerbate hypertension and promote progression to preeclampsia, limiting its use (16).

Ketoconazole has been shown to be effective in some patients, but it may cause intrauterine growth restriction. Cyproheptadine is not recommended because of lack of efficacy (17). Aminoglutethimide and mitotane are contraindicated; the former can induce fetal masculinization, whereas the latter has teratogenic effects (16).

Pregnancy is the only physiological state of hypercortisolism. CS in pregnancy poses a challenge to physicians because of its association with maternal and fetal morbidities. Altered cortisol circadian rhythm appears to be particularly important for the diagnosis of CS during pregnancy; it should be considered, along with imaging, to have a high clinical index of suspicion. Antepartum fetal surveillance and intensive control of maternal blood pressure and glycemia are mandatory interventions. Treatment must be designed as per the individual patient's condition to guarantee good outcomes.

---

#### Patient's perspective

At the beginning, weight gain and excessive hair growth on my body highly concerned me because I did not know what was going on. When doctors told me that I had a tumor in one of my adrenal glands, I was afraid because they also told me that there was a high risk to my baby's health. When I left the hospital, I felt relieved because my blood pressure and blood sugar were controlled. However, the loss of my baby later on was a shocking experience for me. Thankfully, I had good support at home and at the hospital and I recovered emotionally. Currently, I am compliant with my medications and with my follow-up appointments. Everything looks controlled now.

---

#### Declaration of interest

The authors declare that there is no conflict of interest that could be perceived as prejudicing the impartiality of the research reported.

---

#### Funding

This case report did not receive any specific grant from any funding agency in the public, commercial or not-for-profit sector.

---

#### Patient consent

Written informed consent for publication of their clinical details and clinical images was obtained from the patient.

**Author contribution statement**

Sofia Pilar Ildelfonso-Najarro was part of the treating team and was the main writer and case reviewer and conducted literature overview. Esteban Alberto Plasencia-Dueñas was part of the treating team and contributed to the writing of the body of the text. Cesar Joel Benites-Moya was a case reviewer, translator and editor and prepared the manuscript. Jose Carrion-Rojas was part of the treating team and a case reviewer. Marcio Jose Concepción-Zavaleta was part of the treating team and contributed to the writing of the body of text, was a case reviewer and conducted literature overview.

**References**

- 1 Caimari F, Valassi E, Garbayo P, Steffensen C, Santos A, Corcoy R & Webb SM. Cushing's syndrome and pregnancy outcomes: a systematic review of published cases. *Endocrine* 2017 **55** 555–563. (<https://doi.org/10.1007/s12020-016-1117-0>)
- 2 Zhang X, Liao H, Zhu X, Shi D & Chen X. A successful pregnancy in a patient with secondary hypertension caused by adrenal adenoma: a case report. *BMC Pregnancy and Childbirth* 2019 **19** 116. (<https://doi.org/10.1186/s12884-019-2262-2>)
- 3 Lin W, Huang HB, Wen JP, Wang NY, Wang SY, Wang C & Chen G. Approach to Cushing's syndrome in pregnancy: two cases of Cushing's syndrome in pregnancy and a review of the literature. *Annals of Translational Medicine* 2019 **7** 490. (<https://doi.org/10.21037/atm.2019.07.94>)
- 4 Andreescu CE, Alwani RA, Hofland J, Looijenga LHJ, De Herder WW, Hofland LJ & Feelders RA. Adrenal Cushing's syndrome during pregnancy. *European Journal of Endocrinology* 2017 **177** K13–K20. (<https://doi.org/10.1530/EJE-17-0263>)
- 5 Brue T, Amodru V & Castinetti F. Management of Endocrine Disease: management of Cushing's syndrome during pregnancy: solved and unsolved questions. *European Journal of Endocrinology* 2018 **178** R259–R266. (<https://doi.org/10.1530/EJE-17-1058>)
- 6 Prebtani AP, Donat D & Ezzat S. Worrisome striae in pregnancy. *Lancet* 2000 **355** 1692. ([https://doi.org/10.1016/s0140-6736\(00\)02242-x](https://doi.org/10.1016/s0140-6736(00)02242-x))
- 7 Lindsay JR, Jonklaas J, Oldfield EH & Nieman LK. Cushing's syndrome during pregnancy: personal experience and review of the literature. *Journal of Clinical Endocrinology and Metabolism* 2005 **90** 3077–3083. (<https://doi.org/10.1210/jc.2004-2361>)
- 8 Sheeler LR. Cushing's syndrome and pregnancy. *Endocrinology and Metabolism Clinics of North America* 1994 **23** 619–627. ([https://doi.org/10.1016/S0889-8529\(18\)30088-4](https://doi.org/10.1016/S0889-8529(18)30088-4))
- 9 Buescher MA, McClamrock HD & Adashi EY. Cushing's syndrome in pregnancy. *Obstetrics and Gynecology* 1992 **79** 130–137.
- 10 Lindsay JR & Nieman LK. Adrenal disorders in pregnancy. *Endocrinology and Metabolism Clinics of North America* 2006 **35** 1–20, v. (<https://doi.org/10.1016/j.ecl.2005.09.010>)
- 11 Ambroziak U, Kondracka A, Bartoszewicz Z, Krasnodebska-Kiljanska M & Bednarczuk T. The morning and late-night salivary cortisol ranges for healthy women may be used in pregnancy. *Clinical Endocrinology* 2015 **83** 774–778. (<https://doi.org/10.1111/cen.12853>)
- 12 Lekarev O & New MI. Adrenal disease in pregnancy. *Best Practice and Research: Clinical Endocrinology and Metabolism* 2011 **25** 959–973. (<https://doi.org/10.1016/j.beem.2011.08.004>)
- 13 Choi WJ, Jung TS & Paik WY. Cushing's syndrome in pregnancy with a severe maternal complication: a case report. *Journal of Obstetrics and Gynaecology Research* 2011 **37** 163–167. (<https://doi.org/10.1111/j.1447-0756.2010.01339.x>)
- 14 Shaw JA, Pearson DW, Krukowski ZH, Fisher PM & Bevan JS. Cushing's syndrome during pregnancy: curative adrenalectomy at 31 weeks gestation. *European Journal of Obstetrics, Gynecology, and Reproductive Biology* 2002 **105** 189–191. ([https://doi.org/10.1016/s0301-2115\(02\)00148-3](https://doi.org/10.1016/s0301-2115(02)00148-3))
- 15 Blanco C, Maqueda E, Rubio JA & Rodriguez A. Cushing's syndrome during pregnancy secondary to adrenal adenoma: metyrapone treatment and laparoscopic adrenalectomy. *Journal of Endocrinological Investigation* 2006 **29** 164–167. (<https://doi.org/10.1007/BF03344091>)
- 16 Lindsay JR & Nieman LK. The hypothalamic-pituitary-adrenal axis in pregnancy: challenges in disease detection and treatment. *Endocrine Reviews* 2005 **26** 775–799. (<https://doi.org/10.1210/er.2004-0025>)
- 17 Khir AS, How J & Bewsher PD. Successful pregnancy after cyproheptadine treatment for Cushing's disease. *European Journal of Obstetrics, Gynecology, and Reproductive Biology* 1982 **13** 343–347. ([https://doi.org/10.1016/0028-2243\(82\)90069-7](https://doi.org/10.1016/0028-2243(82)90069-7))

Received in final form 14 March 2020

Accepted 23 March 2020