



Artículo Original

Aortic valve replacement through minithoracotomy. Results from the Peruvian experience

Josías C. Ríos-Ortega^{1,a}, Josué Sisniegas-Razón^{1,a}, Roger Conde-Moncada^{1,a}, Yemmy Pérez-Valverde^{1,a}, Julio Morón-Castro^{1,a}

Received: May 01, 2022
Accepted: June 30, 2022

Authors affiliation

¹ Departamento de Cirugía Cardiovascular, Instituto Nacional Cardiovascular INCOR- EsSalud, Lima, Perú.

^a Medical Doctor.

Corresponding author

Josías Caleb Ríos Ortega
Jirón Coronel Zegarra 417. Jesús María. Lima. Perú
+511 985794462; +511 4111560
jcrioso40@hotmail.com

E-mail

jcrioso40@hotmail.com

Conflict of interest

None declared.

Funding statements

This work was supported by self-financing.

Cite as

Ríos-Ortega JC, Sisniegas-Razón J, Conde-Moncada R, Pérez-Valverde Y, Morón-Castro J. Aortic valve replacement through minithoracotomy. Results from the Peruvian experience. Arch Peru Cardiol Cir Cardiovasc. 2022;3(2):127-131. doi: 10.47487/apcyccv.v3i2.219.



Esta obra tiene una licencia de Creative Commons Atribución 4.0 Internacional

ABSTRACT

Objectives. To assess mortality, major valve-related events (MAVRE), and other complications in the perioperative period and follow up in patients with aortic valve replacement (AVR) through minithoracotomy (MT). **Methods.** We retrospectively analyzed patients aged <80 who underwent AVR through MT between January 2017 and December 2021 in a national reference center in Lima, Peru. Patients undergoing other surgical approaches (mini-sternotomy, etc.), other concomitant cardiac procedures, redo, and emergency surgeries were excluded. We measured the variables (MAVRE, mortality, and other clinical variables) at 30 days and a mean follow-up of 12 months. **Results.** Fifty-four patients were studied, the median age was 69.5 years, and 65% were women. Aortic valve (AV) stenosis was the main indication for surgery (65%), and bicuspid AV represented 55.6% of cases. At 30-days, MAVRE occurred in two patients (3.7%), with no in-hospital mortality. One patient had an intraoperative ischemic stroke, and one required a permanent pacemaker. No patient underwent reoperation due to prosthesis dysfunction or endocarditis. In a mean follow-up of one year, MAVRE occurrence did not show variations with the perioperative period, most patients remained in NYHA I (90.7%) or II (7.4%) compared to the preoperative period ($p < 0.001$). **Conclusions.** AV replacement through MT is a safe procedure in our center for patients under 80 years.

Keywords: Aortic valve; Thoracotomy; Cardiac Surgery; Peru (source: MeSH).

RESUMEN

Reemplazo de válvula aórtica mediante minitoracotomía. Resultados de la experiencia peruana

Objetivos. Evaluar la mortalidad, los eventos mayores relacionados con la válvula (EMRV) y otras complicaciones en el período perioperatorio y de seguimiento en pacientes con sustitución de la válvula aórtica (SVA) mediante minitoracotomía (MT). **Métodos.** Analizamos retrospectivamente a pacientes menores de 80 años, a quienes se les realizó SVA por MT entre enero de 2017 y diciembre de 2021 en un centro de referencia nacional en Lima, Perú. Se excluyeron pacientes sometidos a otros abordajes quirúrgicos (mini-sternotomía, etc.), otros procedimientos cardíacos concomitantes, cirugías de reoperación y de emergencia. Medimos las variables (mortalidad, EMRV y otras variables clínicas) a los 30 días y un seguimiento medio de 12 meses. **Resultados.** Se estudiaron 54 pacientes, la mediana de edad fue de 69,5 años y el 65% fueron mujeres. La estenosis de la válvula aórtica (VA) fue la principal indicación para la cirugía (65%) y la VA bicúspide representó el 55,6% de los casos. A los 30 días, se produjeron dos EMRV (3,7%) y no hubo mortalidad intrahospitalaria. Un paciente tuvo un accidente cerebrovascular isquémico intraoperatorio y uno requirió un marcapasos permanente. Ningún paciente fue reoperado por disfunción de la prótesis o endocarditis. En un seguimiento medio de un año, la aparición de EMRV no mostró variaciones con el período perioperatorio; la mayoría de los pacientes permaneció en clase funcional NYHA I (90,7%) o II (7,4%) en comparación con el período preoperatorio ($p < 0,001$). **Conclusiones.** La sustitución de la válvula aórtica mediante minitoracotomía es un procedimiento seguro en nuestro centro en pacientes <80 años.

Palabras clave: Válvula Aórtica; Toracotomía; Cirugía Cardíaca; Perú (fuente: DeCS).

Introduction

Aortic valve (AV) stenosis is the most common heart valve disease and is an important public health problem^(1,2); Despite advances in trans-catheter therapy, surgical AV replacement remains the gold standard therapy, especially in young and low-risk patients⁽³⁾. For this surgery, full median sternotomy (FMS) has been the approach of choice, offering wide access to cardiac anatomy and extensive exposure to the great vessels.

However, FMS has serious complications, such as disruption of the sternum and mediastinal infection that occur in 0.3-5% of cases, and these problems are associated with a mortality rate between 14 and 47%⁽⁴⁾. Pain is another complication that in many cases is disabling for a long period⁽⁵⁾. Formation of abnormal scars is a significant source of morbidity following sternotomy and this the presence of this scar causes alterations in body image, self-esteem, and cosmetic outcomes^(6,7).

Therefore, surgical approaches have been sought to avoid FMS (mini-J or T sternotomy, mini-thoracotomy [MT]) since few decades. There are currently many centers worldwide that perform minimally invasive procedures for AV replacement, and these approaches have been shown to reduce pain, hospital stay, postoperative atrial fibrillation rate, and surgical site infectious complications⁽⁸⁻¹⁰⁾.

We present the surgical results in patients who underwent AV replacement through MT approach performed in our center.

The objective of this first report in our country, is to determine procedure's safety measured through total mortality and major adverse valve-related events (MAVRE).

Materials and methods

Design

We conducted a retrospective research of patients who were submitted to AV replacement through MT approach from January 2017 to December 2021 in the Instituto Nacional Cardiovascular - EsSalud, Lima, Peru. Patients older than 80 years, patients undergoing other surgical approaches (mini-sternotomy, etc.), other concomitant cardiac procedures (replacement of the ascending aorta, other valve surgeries, coronary bypass, etc.), redo and emergency surgeries were excluded.

Operative technique

All surgeries were performed during cardioplegic arrest on cardiopulmonary bypass (CPB) and underwent intraoperative transesophageal echocardiography in addition to standard monitoring for cardiac surgery.

For MT we opened the third intercostal space (**Figure 1A, 1B**) and detach the upper or lower rib from its junction with the sternum, previously ligating the right internal mammary artery, in all cases for CPB we cannulated right femoral artery

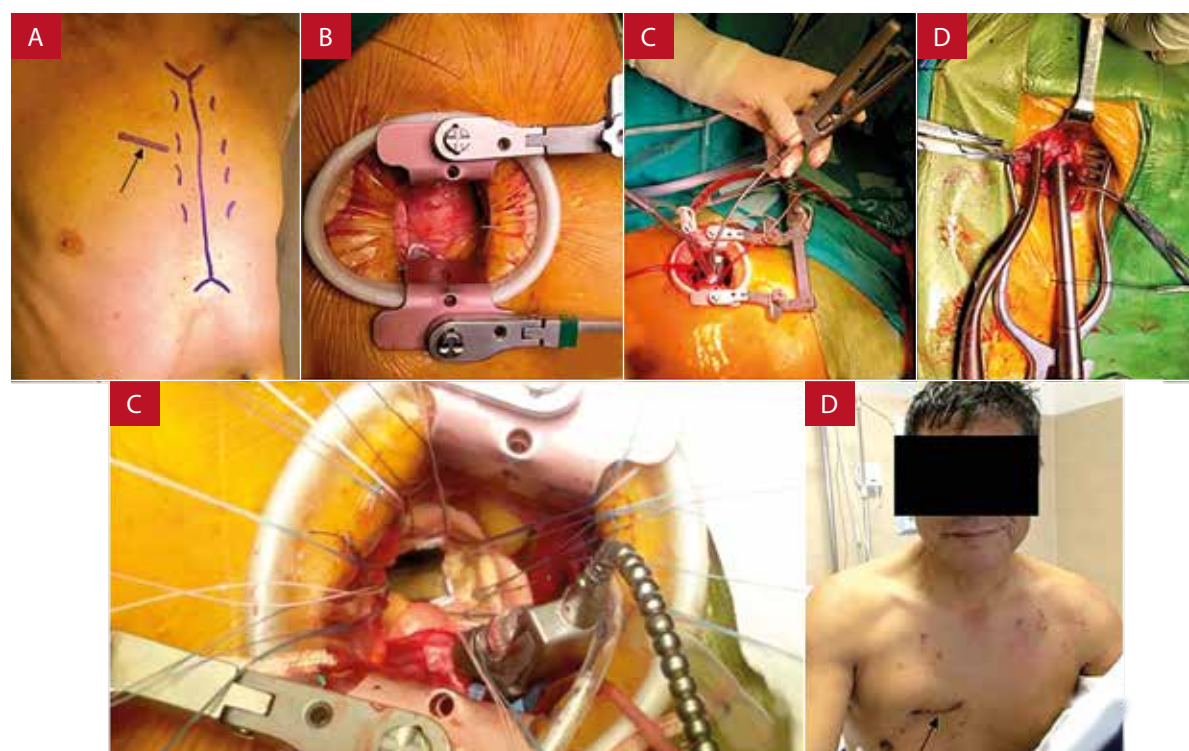


Figure 1. A. Incision site (arrow). B. View of the ascending aorta after mini-thoracotomy. C. Aortic cross clamping with a flexible clamp. D. Femoral artery and vein cannulation. E. Aortic ring after removing the AV and placing sutures. F. Final result.

and vein (Figure 1D). Aortic cross clamping was performed with percutaneous clamp through the second/third intercostal space (anterior axillary line) or with a flexible-articulated clamp (Figure 1C). We use crystalloid cardioplegic solution for myocardial protection (HTK Custodiol®) and placed it in the aortic root or directly into coronary ostia. Aortotomy was performed conventionally and then we performed AV replacement using surgical instruments for MT (Figure 1E, 1F).

Data collection

Data was collected using the physical and electronic medical records of the patients at three times: baseline (during hospital admission before to the surgical procedure), during the perioperative period (surgery procedures, in the intensive care unit (ICU) and during the first 30 postoperative days), and in the follow-up to 12 months after surgery.

Outcomes

The primary clinical outcome was procedure’s safety, measured through total mortality and MAVRE (10) which included valve-related mortality, any structural or nonstructural prosthesis dysfunction, valve thrombosis, embolism, bleeding, prosthetic valve endocarditis, reoperation, or permanent pacemaker insertion. The secondary endpoint of the study was determining the hospital stay, surgical re-interventions due to excessive bleeding, among other clinical variables.

Statistical analysis

We explored the distribution of variables using analytical and graphical methods and reported numerical data. Variables that meet normality criteria were expressed as mean and standard deviation, and those that do not meet normality criteria were expressed as median and interquartile range (IQR). Categorical variables were expressed in absolute and relative frequencies in the baseline, perioperative and follow-up periods. We estimated the cumulative incidence of mortality and MAVRE in the perioperative period and during follow up. Also, we used chi-square test for comparing functional class.

Results

Baseline and surgical characteristics

We included 54 patients in our analysis. Preoperative baseline profiles of the patients are listed in Table 01. Sixty-five percent were women, and the median age was 69.5 years (IQR: 64.5 – 74.5). Most patients had functional class III before surgery (63%). AV stenosis was the main indication for surgery (65%) and bicuspid AV represented 55.6% of cases. Median EuroScore II before surgery was 0.87.

Early Postoperative results

We mainly perform biological AV replacements (81.5%), median aortic cross-clamping (ACC) and cardiopulmonary bypass (CPB) times were 109 and 145 min, respectively. In seven patients we

Table 1. Baseline characteristics

Item	Frequency
Age (years)-----median (IQR)	69.5 (64.5-74.5)
Sex	
male-----n (%)	19 (35)
Female-----n (%)	35 (65)
BMI (kg/m ²) -----median (IQR)	25 (22.65-27.35)
BMI≥30 -----n (%)	5 (9.3)
Functional Class (NYHA) ---n (%)	
II	20 (37)
III	34 (63)
AV disease-----n (%)	
Stenosis	35 (65)
Regurgitation	19 (35)
AV morphology-----n (%)	
Bicuspid	30 (55.6)
Tricuspid	24 (44.4)
AV annulus (mm)-----median (IQR)	23.5 (22.0-26.5)
≤21mm -----n (%)	10 (18.5)
AV peak gradient (mmHg) ---median (IQR)	90 (78-114)
AV mean gradient (mmHg) --median (IQR)	57.5 (47-78.5)
LVEF (%)-----median (IQR)	65 (60-70)
Other basal characteristics ----n (%)	
Hypertension	24 (44)
Diabetes	10 (19)
Chronic atrial fibrillation	1 (1.9)
Dialysis	0 (0)
EuroScore II (%)-----median (IQR)	0.87 (0.685-1.24)

BMI=Body mass index; kg=Kilogram; m=Meter; NYHA=New Year Heart Association; AV= Aortic valve; LVEF=Left ventricular ejection fraction; SD=Standard deviation, replacement; IQR=Interquartile range.

performed aortic root enlargement Table 02 shows others surgical characteristics.

At 30 days, MAVRE occurred in two patients (3.7%), we had no in-hospital mortality, one patient had an intraoperative ischemic

Table 2. Surgical procedures characteristics

Item	Frequency
CPB time (min)-----median (IQR)	145 (128-162)
ACC time (min)----- median (IQR)	109 (92-126)
Prosthesis type -----n (%)	
Mechanical	10 (18.5)
Biological	45 (81.5)
Aortic root enlargement-----n (%)	7 (13)
Prosthesis size -----n (%)	
19 mm	1 (1.9)
21 mm	25 (46.3)
23 mm	15 (27.8)
25 mm	13 (24.1)

CPB=Cardiopulmonary Bypass; ACC= Aortic cross clamp.

stroke, and another required a permanent pacemaker. No patient underwent reoperation due to prosthesis dysfunction or endocarditis. Two patients (3%) required surgical re-intervention due to excessive bleeding. Prolonged intubation (>48h) was present in 3 patients (5.56%). No mediastinitis or perioperative infarction were observed. Other characteristics are shown in **Table 03**.

Follow-up results

In a mean follow-up of one year, we had two MAVRE: one patient with stroke and one permanent pacemaker insertion (3.7% of cases), no mortality cases were reported. Regarding symptomatology, most patients remained in NYHA I (90.7%) or II (7.4%) functional class, compared to the preoperative period (NYHA I: 0%, NYHA II: 37%), this difference was significant (p<0.001).

Discussion

symptomatic severe aortic stenosis is associated with high mortality rates, ~ 50% at 1 year, and the prevalence will likely increase as the population ages. In this pathology, interventional procedures (AV replacement) have been shown to drastically reduce mortality and improve quality of life (2,11). The development of trans catheter AV replacement has changed the treatment of

Table 4. Follow-up evolution (average 12 months)

Primary end-point	
Total Mortality-----n (%)	0 (0)
MAVRE-----n (%)	2 (3.7)
Valve-related mortality	0 (0)
Valve-related morbidity	
Stroke	1 (1.9)
Structural dysfunction	0 (0)
Nonstructural dysfunction	0 (0)
Major Bleeding	0 (0)
Redo surgery for infective endocarditis	0 (0)
Definitive Pacemaker	1 (1.9)
Functional class (NYHA) ---n (%)	
I	49 (90.7)
II	4 (7.4)
III	1 (1.8)

MAVRE=Major adverse valve relative event; NYHA=New Year Heart Association.

patients with severe aortic stenosis. However, for young and low risk individuals, surgery remains the preferred treatment option. Moreover, the advent of sutureless aortic prostheses has increased the ease of minimally invasive surgery for AV replacement (2,12). Minimally invasive cardiac surgeries have been performed since the early 1990s, seeking alternatives to reduce the complications of FMS (9,13). In our study, the first in our country, and one of the few published in Latin-American, we found excellent mortality and MAVRE rates (0% and 3.7%, respectively) in patients undergoing AVR through MT.

Mortality and MAVRE

Mini-invasive AV replacement had shown no mortality rates differences compared to conventional aortic valve replacement (14,15). In our series, which includes only patients under 80 years of age, we had no 30-day mortality; however, one patient suffered an ischemic stroke with severe cognitive sequelae and another patient required pacemaker placement due to complete atrioventricular block. A meta-analysis found a crude incidence of early/hospital mortality of 1.4% and 2.2% with minimally invasive and conventional approaches, respectively, and the incidence of postoperative stroke was 1.5% -1.7% (17).

Other clinical Variables

Patients undergoing AVR through mini-invasive approaches spent on average 2.1 (1.6 to 2.7) days less in the hospital (17), mini-invasive approach for AV replacement has been shown to reduce the stay in the ICU, the hospital stay, the pain and the postoperative bleeding (14-17). In our series the median of ICU stay was 3 days, and the median of postoperative bleeding was 500 ml in the first 24 hours. These data are comparable with other series (14-17). CPB and ACC times are longer than FMS in some series, however this has not resulted in an increase in postoperative complications (14-16). In

Table 3. Early post-operative evolution (first 30 days)

Primary end-point	
Total Mortality-----n (%)	0 (0)
MAVRE-----n (%)	2 (3.7%)
Valve-related mortality	0 (0)
Valve-related morbidity	
Stroke	1 (1.9)
Structural dysfunction	0 (0)
Nonstructural dysfunction	0 (0)
Major Bleeding	0 (0)
Definitive Pacemaker	1 (1.9)
Secondary end-point-----median (IQR)	
ICU stay (days)	3 (2-4)
In hospital stay (days)	12 (9-15)
Postoperative bleeding(ml)	500 (400-600)
Other clinical variables-----n (%)	
Redo-surgery for excessive bleeding	2 (3.7)
Prolonged mechanical ventilation	3 (5.56)
Perioperative myocardial infarction	0 (0)
Mediastinitis	0 (0)
Echocardiographic findings	
Peak AV gradient-----median (IQR)	29.5 (21.5-37.5)
Mean AV gradient-----median (IQR)	15 (9-21)
LVEF-----median (IQR)	61.5 (58.5-64.5)
Severe mismatch -----n (%)	0 (0)

MAVRE=Major adverse valvar relative event; ICU=Intensive care unit; LVEF=Left ventricular ejection fraction; SD=Standard deviation.

our study the medians of ACC and CPB times were comparable with those studies.

Regarding the mini-invasive approach, there are two techniques: MT and upper mini-sternotomy (MS). In various meta-analyses there were no difference in operative mortality or stroke incidence between both techniques^(17,18). However Meta-analyses favored MT over MS in reoperation for bleeding (OR: 0.42, 95% CI: 0.28-0.63; $P < 0.001$), aortic cross-clamp time (standardized mean difference: -0.12 , 95% CI: -0.20 to 0.029 ; $P = 0.009$), and the rate of conversion to sternotomy (OR: 0.32, 95% CI: 0.11-0.93; $P = 0.036$). The rate of permanent pacemaker insertion approached borderline significance in favor of MS (OR: 0.54, 95% CI: 0.26-1.12; $P = 0.097$)⁽¹⁸⁾.

One benefit that has been overlooked by most studies is the better cosmetic results that minimally invasive surgery obviously has. Although this was not one our objectives, some studies have shown that a minimally invasive approach has advantages in terms of body image, self-esteem, and aesthetic results over the conventional approach in patients undergoing cardiac surgery⁽⁷⁾.

Despite the advantages of minimally invasive surgery in AVR described above, the experience is still scarce in Latin America. Some reports have been previously published for AVR through

MS o MT showing good results and low rates of mortality and postoperative complications; however, experience is still scant^(19,20).

Limitations and strengths

Our study must be interpreted in the light of its limitations. First, despite few patients were included and it may suppose a low statistical power and high risk of random error. Second, the follow-up time was short and it was not standardized among participants. Third, the data was extracted from medical records, so we cannot guarantee data quality control. On the other hand, our study also has several strengths: it is the first published in our country to show results in AV replacement using a minimally invasive approach. Future analytic studies with national data comparing AVR via MT versus FMS are needed.

In conclusion, AV replacement by mini-thoracotomy is a safe procedure in our center, in patients under 80 years of age, with good mortality and MAVRE rates.

Authors contribution: All authors contributed to the writing and analysis of the data.

References

1. lung B, Delgado V, Rosenhek R, Price S, Prendergast B, Wendler O, et al. Contemporary presentation and management of valvular heart disease: The EURObservational Research Programme Valvular Heart Disease II Survey. *Circulation*. 2019;140(14):1156-1169. doi: 10.1161/CIRCULATIONAHA.119.041080.
2. Yadgir S, Johnson CO, Aboyans V, Adebayo OM, Adedoyin RA, Afarideh M, et al. Global, regional, and national burden of calcific aortic valve and degenerative mitral valve diseases, 1990-2017. *Circulation*. 2020;141(21):1670-1680. doi: 10.1161/CIRCULATIONAHA.119.043391.
3. Vahanian A, Beyersdorf F, Praz F, Milojevic M, Baldus S, Bauersachs J, et al. 2021 ESC/EACTS Guidelines for the management of valvular heart disease: Developed by the Task Force for the management of valvular heart disease. *Eur Heart J*. 2022;43(7):561-632. doi: 10.1093/eurheartj/ehab395.
4. Losanoff JE, Richman BW, Jones JW. Disruption and infection of median sternotomy: a comprehensive review. *Eur J Cardiothorac Surg*. 2002;21(5):831-9. doi: 10.1016/s1010-7940(02)00124-0.
5. Huang AP, Sakata RK. Pain after sternotomy - review. *Braz J Anesthesiol*. 2016;66(4):395-401. doi: 10.1016/j.bjane.2014.09.013.
6. King KM, McFetridge-Durdle J, LeBlanc P, Anzarut A, Tsuyuki RT. A Descriptive Examination of the Impact of Sternal Scar Formation in Women. *Eur J Cardiovasc Nurs*. 2009;8(2):112-118. doi: 10.1016/j.ejcnurse.2008.08.001
7. İyigün T, Kaya M, Gülbeyaz SÖ, Fıstıkçı N, Uyanık G, Yılmaz B, et al. Patient body image, self-esteem, and cosmetic results of minimally invasive robotic cardiac surgery. *Int J Surg*. 2017;39:88-94. doi: 10.1016/j.jisu.2017.01.105.
8. Svensson LG. Minimal-access "J" or "j" sternotomy for valvular, aortic, and coronary operations or reoperations. *Ann Thorac Surg*. 1997;64(5):1501-3. doi: 10.1016/S0003-4975(97)00927-2.
9. Moreno-Cabral RJ. Mini-T sternotomy for cardiac operations. *J Thorac Cardiovasc Surg*. 1997;113(4):810-1. doi: 10.1016/S0022-5223(97)70252-6.
10. Akins CW, Miller DC, Turina MI, Kouchoukos NT, Blackstone EH, Grunkemeier GL, et al. Guidelines for reporting mortality and morbidity after cardiac valve interventions. *J Thorac Cardiovasc Surg*. 2008;135(4):732-8. doi: 10.1016/j.jtcvs.2007.12.002.
11. Bevan GH, Zidar DA, Josephson RA, Al-Kindi SG. Mortality Due to Aortic Stenosis in the United States, 2008-2017. *JAMA*. 2019;321(22):2236-2238. doi: 10.1001/jama.2019.6292.
12. Powell R, Pelletier MP, Chu MWA, Bouchard D, Melvin KN, Adams C. The Perceval Sutureless Aortic Valve: Review of Outcomes, Complications, and Future Direction. *Innovations (Phila)*. 2017;12(3):155-173. doi: 10.1097/IMI.0000000000000372.
13. Glauber M, Ferrarini M, Miceli A. Minimally invasive aortic valve surgery: state of the art and future directions. *Ann Cardiothorac Surg*. 2015;4(1):26-32. doi: 10.3978/j.issn.2225-319X.2015.01.01.
14. Phan K, Xie A, Di Eusanio M, Yan TD. A meta-analysis of minimally invasive versus conventional sternotomy for aortic valve replacement. *Ann Thorac Surg*. 2014;98(4):1499-511. doi: 10.1016/j.athoracur.2014.05.060.
15. Brown ML, McKellar SH, Sundt TM, Schaff HV. Ministernotomy versus conventional sternotomy for aortic valve replacement: a systematic review and meta-analysis. *J Thorac Cardiovasc Surg*. 2009;137(3):670-679.e5. doi: 10.1016/j.jtcvs.2008.08.010.
16. Ariyaratnam P, Loubani M, Griffin SC. Minimally invasive aortic valve replacement: Comparison of long-term outcomes. *Asian Cardiovasc Thorac Ann*. 2015;23(7):814-21. doi: 10.1177/0218492315587606.
17. Chang C, Raza S, Altarabsheh SE, Delozier S, Sharma UM, Zia A, et al. Minimally Invasive Approaches to Surgical Aortic Valve Replacement: A Meta-Analysis. *Ann Thorac Surg*. 2018;106(6):1881-1889. doi: 10.1016/j.athoracur.2018.07.018.
18. Yousuf Salmasi M, Hamilton H, Rahman I, Chien L, Rival P, Benedetto U, et al, Vohra HA. Mini-sternotomy vs right anterior thoracotomy for aortic valve replacement. *J Card Surg*. 2020;35(7):1570-1582. doi: 10.1111/jocs.14607.
19. Fortunato J, Jeronimo A, Sesca J, Paludo R, Paz M, Paludo L, et al. Troca valvar aórtica minimamente invasiva: uma alternativa à técnica convencional. *Braz J Cardiovasc Surg*. 2012;27(4):570-582. doi: 10.5935/1678-9741.20120099.
20. Benetti F, Rizzardi JL, Concetti C, Bergese M, Zappetti A. Minimally aortic valve surgery avoiding sternotomy. *Eur J Cardiothorac Surg*. 1999;16 Suppl 2:S84-5.