

Case report

Cutaneous inoculation tuberculosis in a healthcare worker: Case report and literature review



F. Soto-Febres^{a,*}, J. Ballena-López^a, D. Alva^b, A. Riboty^c, R. León^d, J. Chang^d, G. Pérez-Lazo^a, J. Hidalgo^a

^aInfectious Diseases Unit, Guillermo Almenara Irigoyen National Hospital, EsSalud. Lima - Peru

^bHead, Neck and Maxillofacial Surgery Service, Guillermo Almenara Irigoyen National Hospital, EsSalud. Lima - Peru

^cEnvironmental and Occupational Health Unit, Guillermo Almenara Irigoyen National Hospital, EsSalud. Lima - Peru

^dPathological and Surgical Anatomy Service, Guillermo Almenara Irigoyen National Hospital, EsSalud. Lima - Peru

ARTICLE INFO

Article history:

Received 29 April 2020

Received in revised form 30 April 2020

Accepted 1 May 2020

Keywords:

Cutaneous tuberculosis

Inoculation

Healthcare worker

ABSTRACT

In all health care settings, particularly those in developing countries, healthcare workers have a high risk for exposure to tuberculosis. Tuberculosis can involve any organ, including the skin. Cutaneous tuberculosis is uncommon and may be secondary to an exogenous inoculation.

We report the case of a surgical resident at a tertiary care hospital in Lima, Peru who developed cutaneous inoculation tuberculosis after sustaining a needlestick injury while performing a diagnostic cervical lymph node aspiration from a patient with HIV infection and tuberculous cervical lymphadenopathy.

© 2020 The Authors. Published by Elsevier Ltd. This is an open access article under the CC BY-NC-ND license (<http://creativecommons.org/licenses/by-nc-nd/4.0/>).

Introduction

Tuberculosis is a known public health problem in Peru, with the second highest incidence in the Americas (116.4 per 100,000 population) [1]. Healthcare workers (HCWs) were found to have an approximately 2 and 3 times greater risk of latent tuberculosis infection and active tuberculosis disease, respectively, compared to the general population [2].

Mycobacterium tuberculosis skin involvement is infrequent and may occur as a result of hematogenous spread, continuity extension of a focus underlying the skin (osteomyelitis, epididymitis or lymphadenitis) and as a result of exogenous inoculation [3].

We identified 21 cutaneous inoculation tuberculosis case reports in HCWs in the literature, including the present case.

Case report

A 26-year-old man surgical resident at a tertiary care hospital in Lima, Peru with no relevant medical history, developed a cutaneous lesion one week after sustaining a needlestick injury in his third left hand finger while performing a cervical

lymphadenopathy aspiration. Source patient had been admitted to the hospital with a known diagnosis of HIV infection, failing HAART and cervical lymphadenopathy. He received prompt HIV post-exposure prophylaxis with tenofovir/emtricitabine and raltegravir with negative baseline and follow up HIV test.

One week after accident swelling and erythema developed in the site of puncture (Fig. 1A). Lesion progressed to ulceration with sero-purulent discharge despite receiving oral and parenteral antimicrobials for 3 weeks. He was admitted for diagnostic work up and surgical management of wound. On examination: He was in good overall condition and vital signs within normal range, throughout the course of illness. A cutaneous skin ulcer was noted in his third finger of left hand with erythema of the ulcer margins and yellowish secretion (Fig. 1B) and limitation of affected finger mobility secondary to presence of the lesion. There were no enlarged regional lymph nodes and the rest of exam unremarkable. Blood-work including complete cell count, liver and renal function and chest and finger radiographs were normal.

A surgical exploration and debridement of the finger lesion was performed and tissue for biopsy and bacterial, fungi and mycobacterial cultures were sent. Histopathologic findings revealed an acute and chronic inflammation, with epithelioid granulomas, Langhan's giant cells and foci of caseous necrosis (Fig. 2A). Ziehl-Neelsen (ZN) stain detected the presence of acid-fast bacilli (Fig. 2B). Six weeks later, tissue culture grew one colony of *Mycobacterium tuberculosis* and Genotype[®] MTBDR Plus showed isoniazid and rifampicin sensitivity.

* Corresponding author.

E-mail addresses: fernandiuss@hotmail.com, fernando.soto.f@upch.pe (F. Soto-Febres).

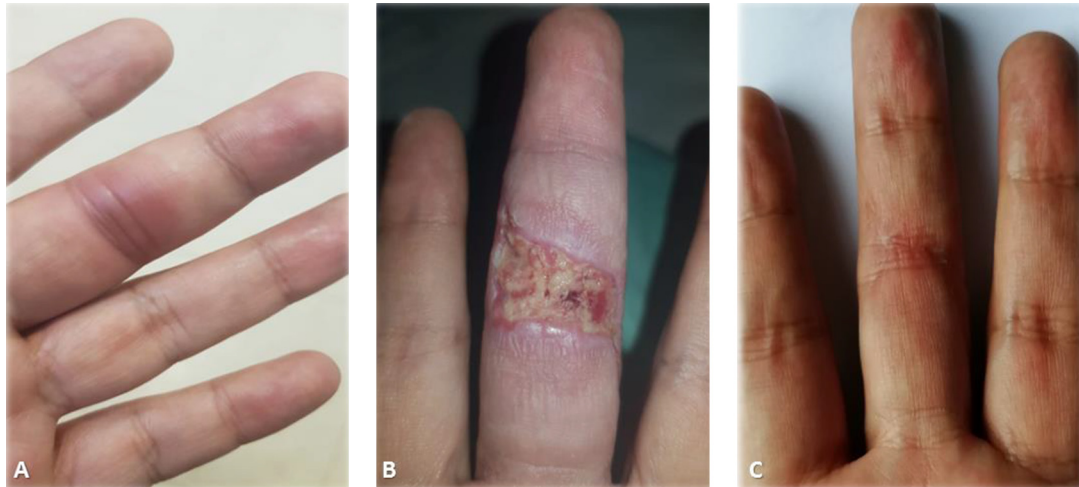


Fig. 1. Cutaneous lesion in third finger of left hand, 1 week after initial injury (A) that progresses to ulceration over the next 3 weeks (B). Complete resolution of skin lesion with full functional after antituberculous treatment (C).

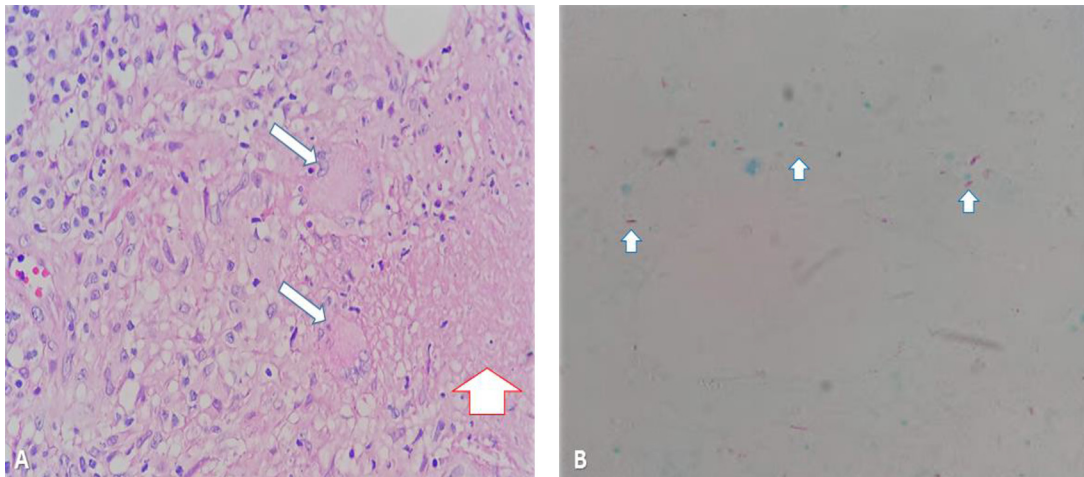


Fig. 2. (A) Chronic inflammation, with epithelioid granulomas with Langhan's giant cells (blue arrows) and foci of caseous necrosis (red arrow). H&E stain, 40 \times . (B) Acid-fast bacilli (small arrows). Ziehl-Neelsen stain, 40 \times .

The patient was treated with weight-adjusted doses of four-drug tuberculosis treatment (isoniazid, rifampin, pyrazinamide and ethambutol) for 2 months followed by 6 months of a two-drug regimen with gradual resolution of lesion (Fig. 1C) and full functional recovery.

Additional management included restriction to perform procedures and direct patient care until complete healing of ulcer.

Discussion

Tuberculosis is one of the most important occupational exposure diseases and is mostly transmitted through inhalation of aerosolized droplets from infected patients [4]. Other mechanisms such as contact direct with secretions [5], through mucous membranes [6] and solutions of continuity of the skin or accidental needlestick or cut [7,8] have been more infrequently described.

Cutaneous tuberculosis from an exogenous source can be classified in primary and post-primary cutaneous inoculation tuberculosis [3]. The primary form results from the entry of mycobacteria into the skin or the mucosa in a tuberculous infection

naïve host, and is characterized by the development of a nodule that progresses into an ulcer with associated regional lymphadenopathy 3–6 weeks after the trauma (cutaneous analog of the Ghon complex in the lungs). The histologic picture can be an acute neutrophilic reaction with areas of necrosis associated with numerous acid-fast bacilli (AFB) during early stages, but 3–6 weeks later, the infiltrate becomes granulomatous and caseous necrosis is evident [3].

On the other hand, in patients with preexisting immunity to tuberculosis, post-primary cutaneous inoculation develops, characterized by a hyperkeratotic papule which eventually becomes verrucous (the prosector's wart described by René Laennec in 1826), that rarely ulcerates, with no adenopathy associated and spontaneous involution, that may occur over several months to years [3].

Our case has characteristics of both types of cutaneous inoculation tuberculosis because the lesion that we describe is an ulcerated erythematous papule without hyperkeratosis and regional lymphadenopathy, in a previously immunized host (BCG vaccine at birth), in which granulomatous inflammation with caseous necrosis were described.

Table 1

Characteristics of cutaneous inoculation tuberculosis reported cases in the literature.

Characteristics	Frequency (n = 21)
Age (years) mean (rank).	33.6 [18–55]
Gender	
Male	9 (43 %)
Female	8 (38 %)
No data	4 (19 %)
Occupational group	
Attending physician	6 (28 %)
Student	6 (28 %)
Physician in training/post-graduate student*	5 (25 %)
Lab technician	3 (14 %)
Nurse	1 (5 %)
Trauma mechanism	
Puncture	13 (62 %)
Laceration/Cut	3 (14 %)
Contact	2 (10 %)
No data	3 (14 %)
Time to initiate symptoms (weeks), mean (rank)**	3.5 [1–8]
Clinical manifestations	
Papule	8
Regional adenopathies	8
Fever	4
Ulcer	3
Pustule	2
Others***	5
Diagnosis	
Histopathological ^a	7 (33 %)
Microbiological ^b + histopathological	7 (33 %)
Microbiological	2 (10 %)
Histopathological + PCR ^c	1 (5 %)
No data	4 (19 %)
Treatment	
Medical (antituberculous drugs)	15 (72 %)
Medical + surgery	3 (14 %)
No data	3 (14 %)
Mortality	0

* Post-graduate student = 1.

** Of 14 cases.

*** Plaque, paronychia, nodule, purulent cellulitis y soft tissue abscess.

^a Observation of histopathological changes of tuberculosis disease of tuberculosis and/or presence of acid-fast bacilli in tissue sample.

^b Observation of acid-fast bacilli in direct examination or positive culture for *M. tuberculosis* complex.

^c PCR: Polimerase Chain Reaction.

We identified 21 cases of cutaneous inoculation tuberculosis in healthcare workers since 1965, including our case [5–19] (Table 1). The mean age was 33 years, with no gender predominance. Physicians were more frequently affected (47 %) than other healthcare workers. The accidental needlestick injury was the main mechanism of trauma in these cases (63 %), as in our case. The most common clinical manifestation of cutaneous inoculation tuberculosis was the papular lesion. Diagnosis was mainly achieved through histopathological studies with or without microbiological criteria (mycobacterial cultures or PCR of tissue, ZN stain of secretions).

Most patients required medical treatment with antituberculous drugs. Three (14 %) required additionally surgery, such as in our case [5–19]. Prophylaxis with isoniazid after exposure has been suggested by some authors, although there is no established post-exposure prophylaxis treatment for these accidents [7,11,19] and is a necessity to evaluate potential prevention regimens for percutaneous exposure to tuberculosis.

As our review shows, 47 % of affected persons were in training (4 physicians in training and 6 students). Hence, it is of great

importance to prevent these accidents with regular information, training and supervision of compliance with protective measures. Our case underscores the possibility of this mechanism of transmission, in particular in areas of high endemicity and limited resources.

Conclusion

Cutaneous inoculation of *M. tuberculosis* in an unusual but potential occupational illness following accidental needlestick. It should be suspected in case of a persistent skin lesion in particular in areas of high endemicity.

Funding

The present study had no sources of funding or sponsorships. It was carried out with own resources of the authors.

Consent

Written informed consent was obtained from the patient for publication of this case report and accompanying images. A copy of the written consent is available for review by the Editor-in-Chief of this journal on request

CRedit authorship contribution statement

F. Soto-Febres: Investigation, Writing - original draft, Writing - review & editing. **J. Ballena-López:** Data curation, Writing - original draft. **D. Alva:** Data curation. **A. Riboty:** Data curation. **R. León:** Data curation. **J. Chang:** Data curation. **G. Pérez-Lazo:** Writing - review & editing. **J. Hidalgo:** Supervision.

Declaration of Competing Interest

The authors declare no conflicts of interest for this article.

References

- [1] Rios Vidal J. Situación de tuberculosis en el Perú y la respuesta del Estado (Plan de Intervención, Plan de Acción). [Internet]. Available from: 2020. <http://www.tuberculosis.minsa.gob.pe/portaldpctb/recursos/20180605122521.pdf>.
- [2] Uden L, Barber E, Ford N, Cooke GS. Risk of tuberculosis infection and disease for health care workers: an updated meta-analysis. *Open Forum Infect Dis* 2017;4(August (3)) ofx137–ofx137.
- [3] Hill MK, Sanders CV. Cutaneous tuberculosis. *Microbiol Spectr* 2017;5(1). [Internet]. Available from: <https://www.asmscience.org/content/journal/microbiolspec/10.1128/microbiolspec.TNMI7-0010-2016>.
- [4] Sharma D, Sharma J, Deo N, Bisht D. Prevalence and risk factors of tuberculosis in developing countries through health care workers. *Microb Pathog* 2018;124 (November):279–83.
- [5] Goette DK, Jacobson KW, Doty RD. Primary inoculation tuberculosis of the skin: prosector's paronychia. *Arch Dermatol* 1978;114(April (4)):567–9.
- [6] Heilman KM, Muschenheim C. Primary cutaneous tuberculosis resulting from mouth-to-mouth respiration. *N Engl J Med* 1965;273(November (19)):1035–6.
- [7] Huang D, Yin H. Primary inoculation tuberculosis after an accidental scalpel injury. *Infection* 2013;41(August (4)):841–4.
- [8] Karoney MJ, Kaumbuki EK, Koech MK, Lelei LK. Primary cutaneous tuberculosis in a 27-year-old medical intern from needle-stick injury: a case report. *Clin Case Rep* 2015;3(January (1)):39–42.
- [9] Sharma VK, Kumar B, Radotra BD, Kaur S. Cutaneous inoculation tuberculosis to laboratory personnel. *Int J Dermatol* 1990;29(May (4)):293–4.
- [10] Hooker RP, Eberts TJ, Strickland JA. Primary inoculation tuberculosis. *J Hand Surg Am* 1979;4(May (3)):270–3.
- [11] Tapias L, Tapias-Vargas LF, Tapias-Vargas LF. Primary cutaneous inoculation tuberculosis in a healthcare worker as a result of a surgical accident. *Int J Dermatol* 2008;47(August (8)):833–5.
- [12] Boccia CM, Gutiérrez M, Benedetti D, Rey D, Faccioli G, González J. Tuberculosis por inoculación. *Rev Am Med Respir* 2012;12(December (4)). [Internet]. Available from: http://www.ramr.org/articulos/volumen_12_numero_4/casisticas/casisticas_tuberculosis_por_inoculacion.php.
- [13] Maestre Naranjo MA, Borda Olivás J, Ortega Hernández A, Tovar Benito E, Rodríguez de la Pinta ML, Daza Pérez RM. Cutaneous tuberculosis accidental inoculation. *Med Segur Trab* 2009;55:65–70.

- [14] Sahn SA, Pierson DJ. Primary cutaneous inoculation drug-resistant tuberculosis. *Am J Med* 1974;57(October (4)):676–8.
- [15] Belchior I, Seabra B, Duarte R. Primary inoculation skin tuberculosis by accidental needle stick. *BMJ Case Rep* 2011;2011(June) bcr1120103496.
- [16] Kramer F, Sasse Sa, Simms Jc, Leedom Jm. Primary cutaneous tuberculosis after a needlestick injury from a patient with AIDS and undiagnosed tuberculosis. *Ann Intern Med* 1993;119(October (7_Part_1)):594–5.
- [17] Ghanbar MI, Bukharie HA. Another hazard to laboratory workers. *Saudi J Med Med Sci* 2015;3(2):174–7.
- [18] Harris SH, Khan R, Verma A, Ahmad S. Finger ulceration in a healthcare professional. *Ann Afr Med* 2010;9(1):45–7.
- [19] Oymak SF, Gülmez Demir R, Özesmi M. Transmission of Mycobacterium tuberculosis by accidental needlestick. *Respiration* 2000;67(6):696–7.